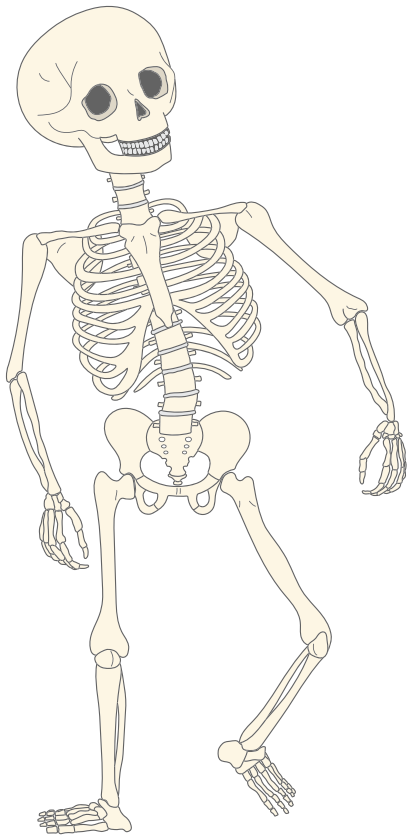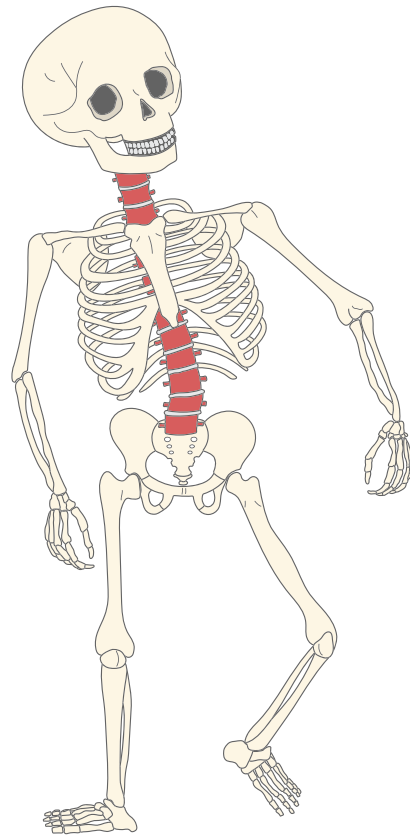
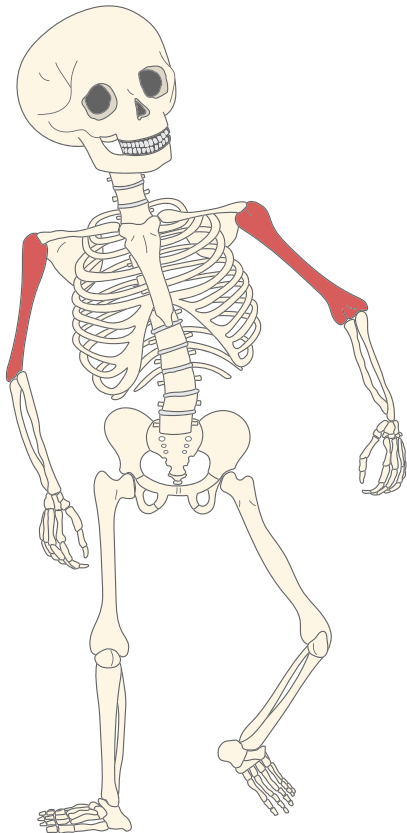


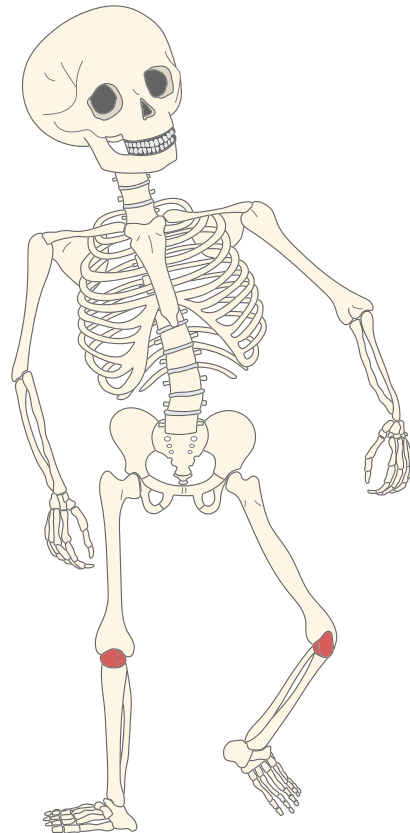
skeleton



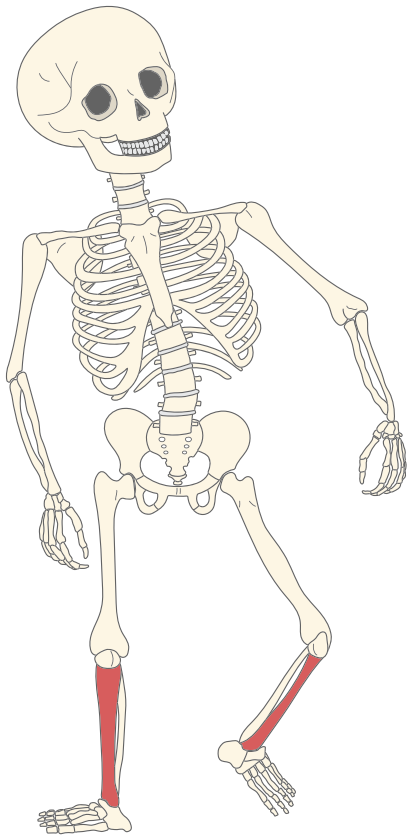
spine



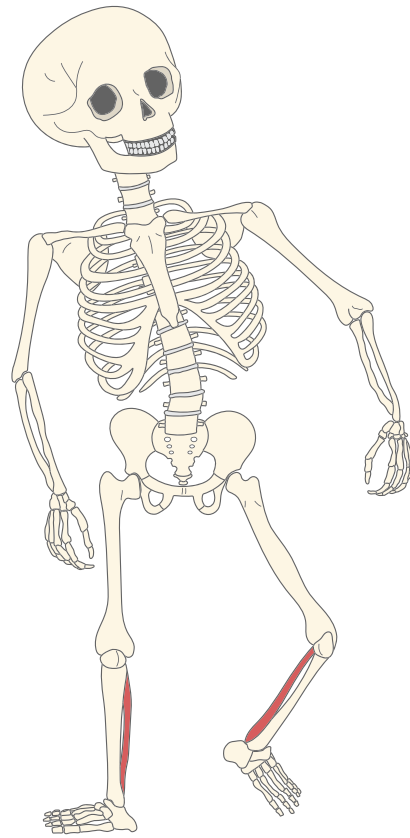
humerus



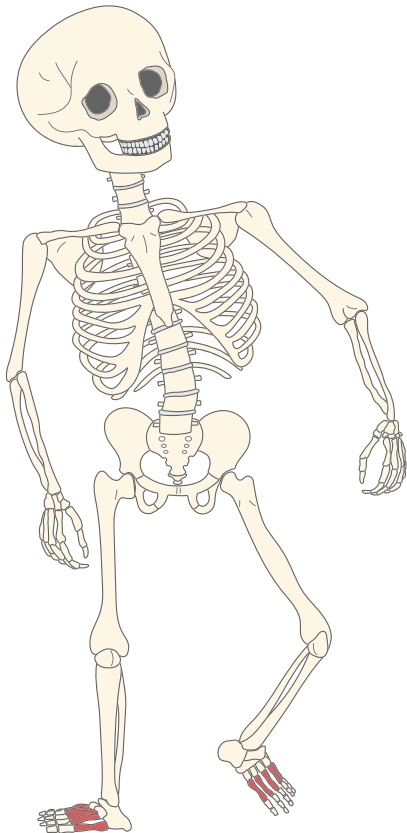
patella



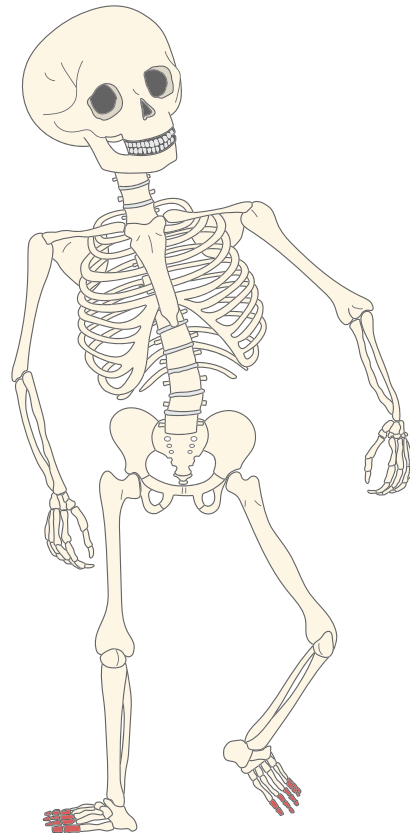
tibia



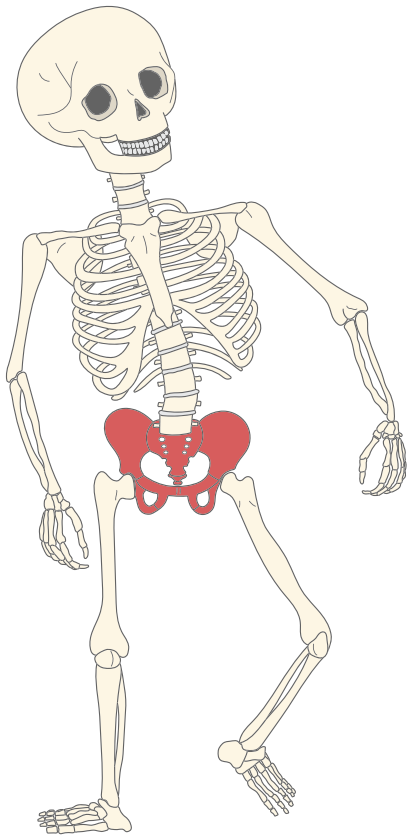
fibula



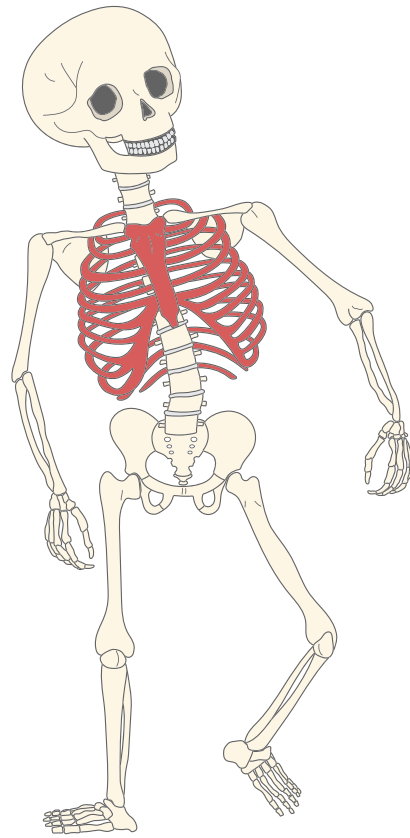
metatarsals



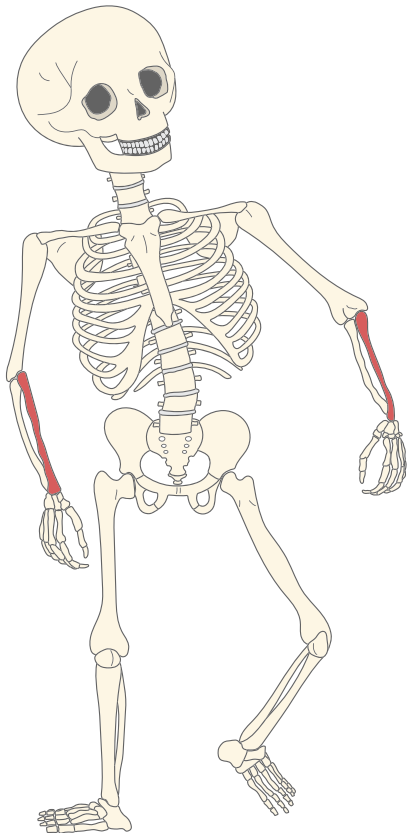
phalanges (toes)



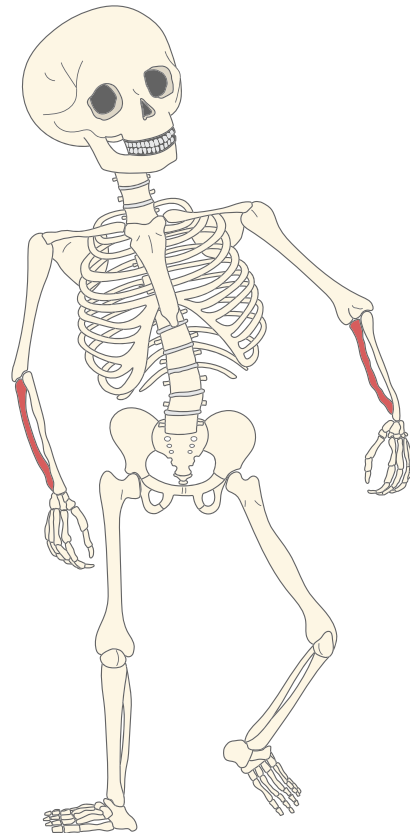
pelvis



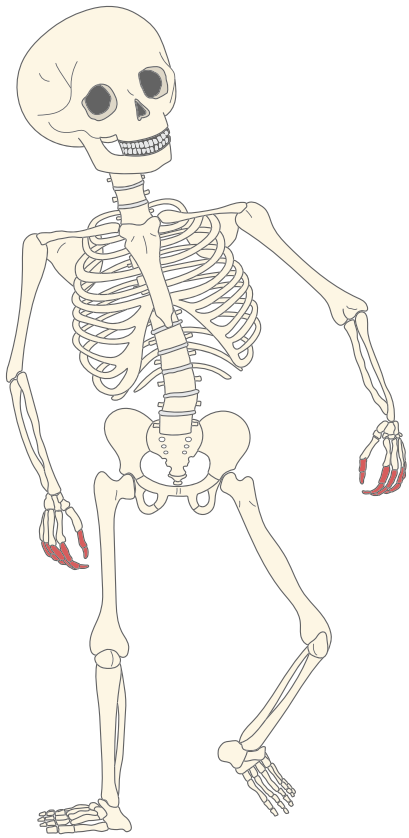
rib cage



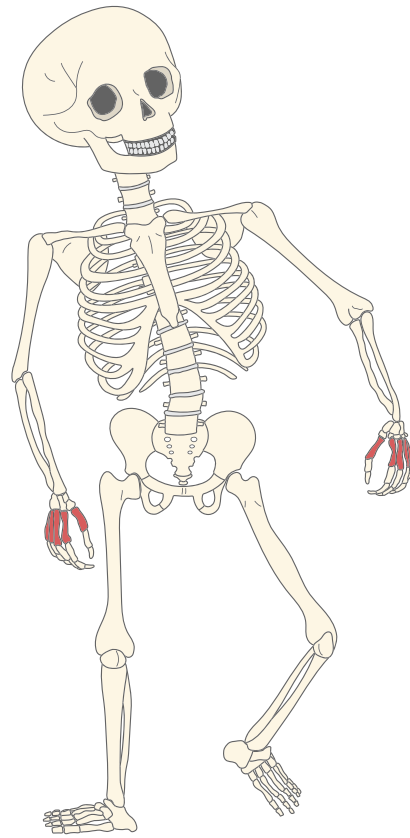
radius



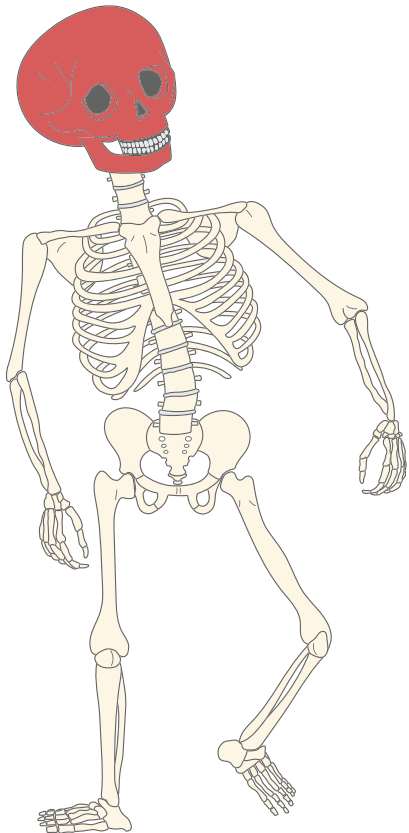
ulna



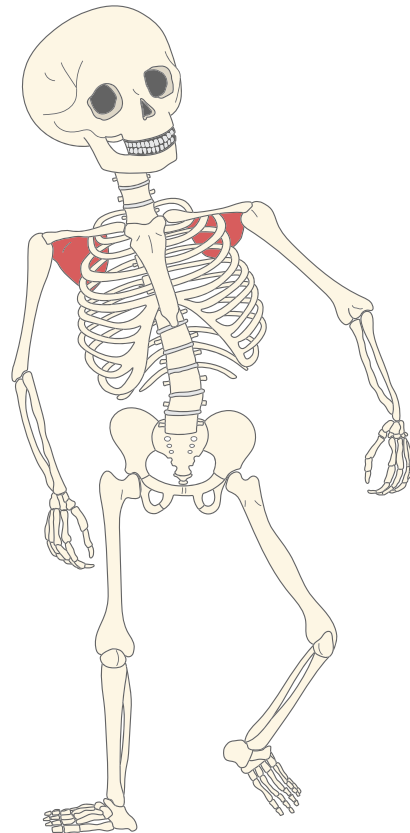
phalanges (fingers)



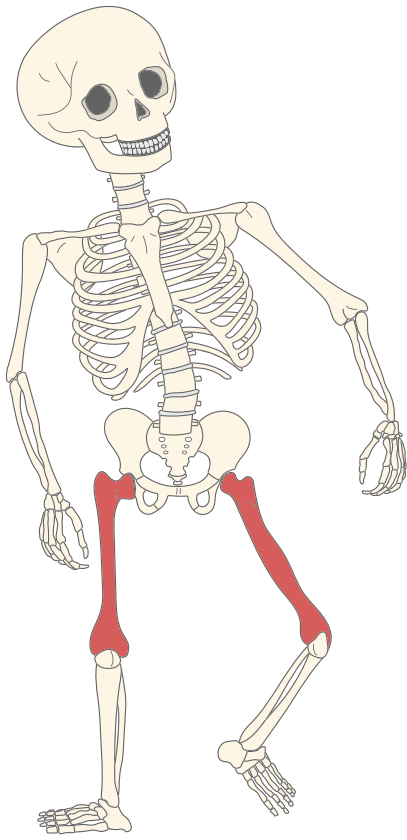
metacarpals



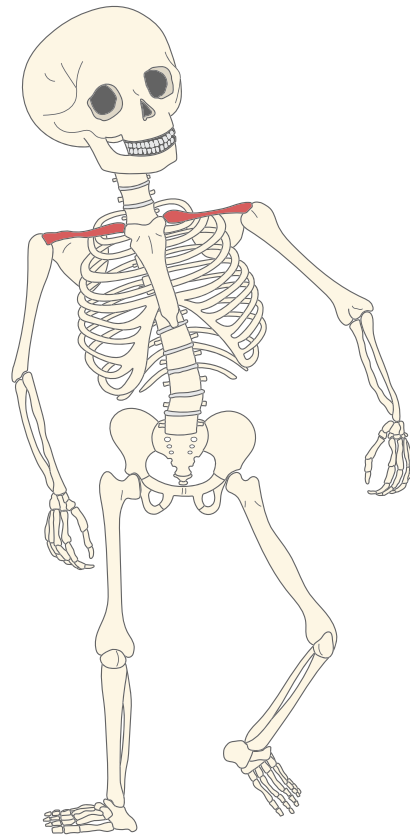
skull



scapula



femur



clavicle